

Quality Resource Guide

Traumatic Injuries and Dislocation of Teeth

Author Acknowledgements

**RENATO SILVA^A, TIMOTHY KIRKPATRICK^B,
ARIADNE LETRA^{A,C}, ZHEN SHEN^B,
JASON KNAPP^B, AUSTYN GRISSOM^B,
HAN NA CHO^B, BAILEY WEIGHTMAN^B**

^A Department of Endodontics, School of Dental Medicine, University of Pittsburgh, Pittsburgh PA

^B Department of Endodontics, UT Health Houston School of Dentistry, Houston TX

^C Department of Oral and Craniofacial Sciences, School of Dental Medicine, University of Pittsburgh, Pittsburgh PA

The authors have no relevant financial relationships to disclose.

Educational Objectives

Following this unit of instruction, the practitioner should be able to:

1. Describe the classification of traumatic dental injuries associated with the dislocation of teeth.
2. Discuss proper management of traumatic dental injuries.
3. Revise timing and chronology of treatment procedures.
4. Discuss prognosis and treatment outcomes.

MetLife designates this activity for **1.0 continuing education credits** for the review of this Quality Resource Guide and successful completion of the post test.

The following commentary highlights fundamental and commonly accepted practices on the subject matter. The information is intended as a general overview and is for educational purposes only. This information does not constitute legal advice, which can only be provided by an attorney.

© 2025 MetLife Services and Solutions, LLC. All materials subject to this copyright may be photocopied for the noncommercial purpose of scientific or educational advancement.

Originally published October 2021. Updated and revised December 2024. Expiration date: December 2027.

The content of this Guide is subject to change as new scientific information becomes available.

ADA CERP® | Continuing Education Recognition Program

Accepted Program Provider FAGD/MAGD Credit 05/01/21 - 06/31/25.

MetLife is an ADA CERP Recognized Provider. ADA CERP is a service of the American Dental Association to assist dental professionals in identifying quality providers of continuing dental education. ADA CERP does not approve or endorse individual courses or instructors, nor does it imply acceptance of credit hours by boards of dentistry. Concerns or complaints about a CE provider may be directed to the provider or to ADA CERP at <https://ccepr.ada.org/en/ada-cerp-recognition>.

Address comments or questions to:

DentalQuality@metlife.com - or -

MetLife Dental Continuing Education

501 US Hwy 22

Bridgewater, NJ 08807

Cancellation/Refund Policy:

Any participant who is not 100% satisfied with this course can request a full refund by contacting us.

Introduction

Traumatic dental injuries are often the result of facial trauma and may affect individuals of all ages. More than one billion individuals and an average of one in four ages 6-50 have experienced dental trauma.^{1,2} Males are more likely to have dental trauma than females.³ Patients will require immediate management at the time of acute injury. However, some patients may also present later reporting a history of traumatic dental injury.⁴

Several types of traumatic dental injuries involve soft and hard tissues, ranging from simple crown fractures (enamel fractures) to more complex and severe types associated with damage to the soft tissues and facial bones. The type and severity of the injury will influence its prognosis and determine the best treatment approach(es); meanwhile, the timing and chronology of treatment procedures are critical to improve the prognosis and save the affected tooth. In most cases, initial treatment for traumatic dental injuries occurs in a hospital setting and with a multidisciplinary care approach involving oral surgeons, general dentists, pediatric dentists, endodontists, periodontists and others. During the initial assessment, it is important that the clinician perform a rapid neurological

exam, looking for signs and symptoms of brain concussion such as dizziness, headache, confusion, visual disturbances, nausea and vomiting and memory loss as well as other signs of injury involving the head and neck. The patient should be referred to a physician for a comprehensive evaluation if the patient displays any of these signs and symptoms or if the dentist suspects there is a possibility of an injury involving the head and neck.

The *International Association of Dental Traumatology* (IADT) offers free updated guidelines in multiple languages for immediate and urgent care of traumatic dental injuries (<https://iadt-dentaltrauma.org/guidelines-and-resources/current-guidelines-2/>).⁵⁻⁸ Dental professionals, auxiliary staff, schoolteachers, coaches and parents may also benefit from the free *ToothSOS* app available through both the IOS and Android app stores.⁹ This app utilizes the latest recommendations from IADT to aid the decision-making process for a traumatic dental injury. The app has an undemanding interface and uses simple language and photos to ensure that anyone (even with no dental training) can follow the proper protocol for immediate management of traumatic dental injuries.

This Quality Resource Guide will focus on the clinical presentations and treatment guidelines for traumatic dental injuries associated with the dislocation of teeth; concussion/subluxation, extrusive luxation, lateral luxation, intrusive luxation and avulsion, to educate dental/health professionals about the management of facial/dental traumatic injuries.

Concussion and Subluxation

Concussion and subluxation may be considered the least severe of the tooth injuries. However, proper diagnosis and care are essential for a favorable prognosis and treatment outcome.

a) Clinical Examination: Concussion involves an injury to a tooth and its supporting structures without fracture or loosening from the alveolus. Symptoms of concussion may include tenderness to percussion and/or palpation. Subluxation involves injury to a tooth and its supporting structures with abnormal loosening from the alveolus, but without displacement.

b) Radiographic Examination: An initial parallel periapical radiograph should be taken. If any radiographic abnormalities are noted, or additional injuries are suspected, additional radiographs with

Table 1 - Clinical presentations and treatment guidelines for concussion and subluxation injuries.

Injury Type	Initial Presentation	Initial Treatment	Follow-up
Concussion	Normal mobility	PA radiograph Pulpal sensibility testing*	Clinical and radiographic follow up at 4 weeks and 1-year post-injury
	Tenderness to percussion or palpation	Additional radiographs/CBCT, if indicated	Treatment is indicated if tooth tests negative to sensibility AND another sign of necrosis or apical periodontitis is present Pulp canal obliteration alone is NOT an indication for endodontic treatment
Subluxation	Abnormal mobility but not displaced	PA radiograph, two off-angle and occlusal radiographs; CBCT Pulpal sensibility testing* Passive, non-rigid splint for two weeks if the tooth is excessively mobile or extremely sensitive to occlusion	Clinical and radiographic follow up at 2 weeks (remove splint), 12 weeks, 6 months and 1 year Treatment is indicated if negative to sensibility testing, AND another sign of pulp necrosis or apical periodontitis is present Particular attention should be directed to look for signs of external inflammatory resorption which requires immediate endodontic therapy with Ca(OH) ₂ canal medication Pulp canal obliteration alone is NOT an indication for endodontic treatment

* The tooth in question may not respond to vitality testing initially

different angulations or a cone-beam computed tomography image (CBCT) should be obtained.

c) Treatment: Although no treatment at the time of injury is indicated, baseline pulp sensibility testing (cold and electric pulp tests) should be performed and recorded for comparison at follow-up appointments. If the tooth is excessively mobile or sensitive to biting, a flexible splint may be used for two weeks to improve the healing of the pulp and/or the periodontal ligament.⁶ A flexible splint allows functional movement of the affected tooth in contrast to a rigid splint where the tooth is immobilized.⁷ An ideal splint should be easily applied and removed without additional trauma to the teeth and surrounding soft tissues, stabilize the injured tooth/teeth in its correct position, and allow physiologic tooth mobility and periodontal ligament reattachment.⁷ The most common types of splints are made of composite and stainless-steel wire (diameter 0.3-0.4mm), composite and fishing line, orthodontic wire (NiTi light 0.014) and bracket, and polyethylene or Kevlar fiber mesh. Materials such as Fiber-Splint (Polydentia SA Mezzovico-Vira, Switzerland), Ribbond™ (Ribbond Inc., Seattle, USA) or EverStick (Stick Tech Ltd, Turku, Finland) are commercially available.⁷

d) Follow-up Examination: Clinical follow-up including periapical radiography, oral examination and pulpal sensibility testing should be performed to monitor for signs of pulp necrosis or apical

periodontitis. Neither pulp canal obliteration nor negative response to testing alone should be considered an indication for endodontic treatment. Root canal therapy should only be considered if additional signs or symptoms indicate pulp necrosis.⁶

Transient pulpal damage or nerve damage without damage to the pulp vasculature may result in false-negative responses to pulp sensibility tests. Normal responses may or may not return with time. In subluxation cases, follow-up appointments are indicated at two weeks, twelve weeks, six months, and one year after the initial injury to monitor for signs of pulp necrosis, apical periodontitis and external inflammatory root resorption. If external inflammatory root resorption develops, endodontic therapy should be immediately initiated using a multi-step approach with placement of calcium hydroxide [Ca(OH)₂] as an intracanal medicament.⁶

Extrusive Luxation

Extrusive luxation is a traumatic dental injury characterized by partial displacement of the tooth vertically from its socket.^{10,11}

a) Clinical Examination: Clinically, a luxated tooth appears elongated in an incisal/axial direction with bleeding around the gingival sulcus. The crown of the tooth is usually displaced palatally. The tooth may present with increased

mobility and will not usually respond to pulp sensibility tests unless the displacement is minor. Due to the outward displacement of the tooth, tenderness to percussion and palpation, and pain during mastication are frequent findings.⁶

b) Radiographic Examination: According to the IADT guidelines, radiographs recommended to diagnose extrusive luxation include one parallel periapical radiograph, two additional periapical radiographs taken at different vertical and/or horizontal angulations and an occlusal radiograph or a CBCT scan, if available.⁶ The extruded tooth will radiographically show a widened periodontal ligament space apically and laterally. As noted on the clinical exam, the tooth will appear longer than the contralateral tooth and will not be seated in its socket.

c) Treatment: Primary teeth - if extrusion is minor (< 3mm), gentle repositioning is indicated. If there is severe extrusive injury (> 3mm), tooth extraction may be indicated.¹²

Permanent teeth - extrusive luxation injuries require immediate treatment to improve the survival chances for the tooth and supporting tissues. After administering local anesthesia and rinsing the area with saline, the tooth should be gently repositioned back into its original location. If a gingival laceration is present, the lacerated area should be sutured. Following repositioning,

Table 2 - Treatment guidelines for extrusive luxation injuries

	Immature (open apex)	Mature (closed apex)
Repositioning	<ol style="list-style-type: none"> 1. Administer local anesthesia. Reposition the tooth by gently pushing it back into its socket. 2. Stabilize the tooth with a passive and flexible splint for two (2) weeks. If a fracture of the marginal bone is noted, splint for an additional four (4) weeks. 3. Suturing may be indicated if a gingival laceration is present. Take a radiograph to confirm correct repositioning and reduction. Advise patient to have soft food for one (1) week and maintain good oral hygiene. 	
Endodontic Considerations	<p>In teeth with open apices, monitor closely for pulp vitality. Pulp canal obliteration is a common finding.</p> <p>If the pulp becomes necrotic, appropriate endodontic therapy for immature teeth (apexification or pulp revascularization) should be initiated as soon as the condition of the tooth permits.</p>	<p>If pulp necrosis is diagnosed, root canal treatment should be initiated to eliminate the infection. Placement of an intracanal medicament or corticosteroid/antibiotic initially followed by Ca(OH)₂ is recommended.</p>

the tooth should be stabilized for two weeks with a passive and flexible splint as described above.⁶ Note: if a marginal bone fracture is also present, the tooth should be splinted for an additional four weeks.⁶ The patient should be instructed to eat soft food for one week and maintain good oral hygiene.

d) Follow-up Examination: Long-term monitoring of the tooth is recommended as post-trauma complications can arise. If the tooth has incomplete root formation, it should be closely monitored for pulp vitality. If the pulp becomes necrotic, either revascularization or apexification can be considered as treatment alternatives. For a tooth with complete root formation, pulp necrosis is the most common consequence, and endodontic treatment is indicated. The recommended follow-up intervals for extrusive injury are two weeks, four weeks, eight weeks, twelve weeks, six months, one year, and yearly for at least five years.⁶ At each follow-up visit, clinical and radiographic evaluations are necessary to detect signs of a normal or healed periodontium. Signs of a favorable outcome include an asymptomatic tooth, absence of marginal bone loss, continued root development in immature teeth and positive response to pulp sensibility testing.⁶ It is important to note that a false-negative response is possible for several months following the trauma. Endodontic treatment should not be initiated based solely

on a negative response from the pulp sensibility testing. Instead, the provider should look for additional signs and/or symptoms to confirm the diagnosis and determine the need for treatment. (Figure 1)

Lateral Luxation

Lateral luxation is a traumatic dental injury resulting in the displacement of the tooth in a lateral direction, usually accompanied by an alveolar fracture or compression of the socket wall or facial cortical bone.⁶ This injury can occur in both the primary and permanent dentition, with similar clinical and radiographic findings for each. Treatment may differ depending on the extent of the injury.^{10,11}

a) Clinical Examination: Clinical findings include tooth displacement, possible fracture of alveolar bone, possible immobility of the affected tooth, occlusal interference, a metallic sound on percussion (suggestive of ankylosis) and often a negative response to pulp sensibility testing.⁶

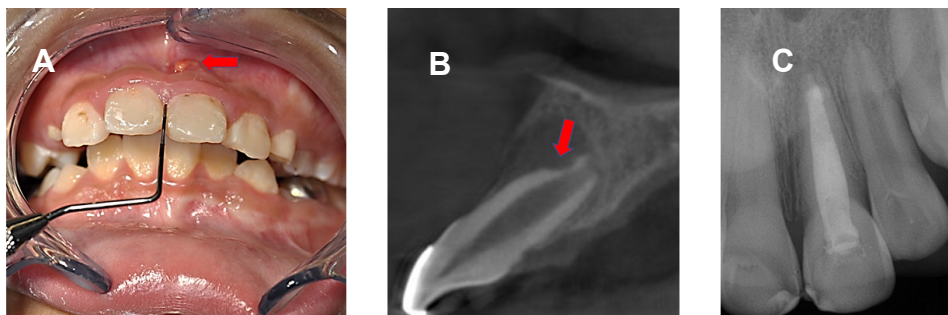
b) Radiographic Examination: Radiographic findings include a widened periodontal ligament space. Multiple angulations of PA radiographs are recommended, including parallel and different horizontal and/or vertical angles. An occlusal radiograph and CBCT are also indicated.⁶

c) Treatment: Treatment recommendations for a **primary tooth** depend on the extent of tooth

displacement.¹² Upon minimal displacement, the tooth may spontaneously reposition itself, usually within six months.¹² In cases of severe tooth displacement, repositioning or extraction of the affected tooth may be considered.¹² If repositioning is completed but the tooth remains unstable, a flexible splint should be placed for four weeks.¹²

Treatment recommendations for lateral luxation of a **permanent tooth** include digitally repositioning the tooth into its socket after local anesthesia is administered.⁶ One method for repositioning involves palpating the gingiva to feel the tooth apex, then using the thumb and index fingers to slightly push the tooth to dislocate it from its post-trauma position and immediately push it back into its socket.⁶ A flexible splint should be applied for four weeks, or if marginal periodontal breakdown is present, additional splinting time may be indicated.⁶ A 2-week follow-up should be scheduled for an endodontic evaluation.⁶ Teeth with incomplete root formation may revascularize with no treatment. If pulp necrosis or external inflammatory root resorption is detected, non-surgical root canal treatment is indicated. Pulp necrosis is a common consequence in teeth with complete root formation. In such cases, non-surgical root canal treatment using intracanal medication with calcium hydroxide to prevent external inflammatory root resorption is indicated.⁶

Figure 1



Clinical and radiographic outcomes of extrusive luxation in a 10-year-old male patient at 15 months post-trauma. Tooth #9 did not respond to cold and electric pulp tests. **A** - A sinus-tract is visible near the mucogingival junction. **B** - CBCT image suggestive of external root resorption (red arrow). Endodontic treatment was completed in 2 sessions after using Ca(OH)₂ paste as intracanal medicament. **C** - Periapical radiograph showing signs of healing of the periapical tissues at the 3-month follow-up visit.

d) Follow-up Examination: Follow-up clinical examination is recommended at one - two weeks, four weeks (for splint removal), six - eight weeks, twelve weeks, six months, and one year.^{6,12} Radiographs are indicated any time pathosis is suspected and symptoms, such as a symptomatic tooth, marginal breakdown of periodontal tissues, signs of pulp necrosis/infection

(sinus tract, gingival swelling, increased mobility), apical periodontitis and ankylosis are present.^{6,12} Patients and their parents should be educated regarding the injury and potential unfavorable outcomes and symptoms.^{6,12} Good oral hygiene and compliance with follow-up visits are essential for the retention of the injured tooth.^{6,12}

Intrusive Luxation

Intrusive luxation involves the displacement of a tooth apically into the alveolar bone. It is relatively infrequent but has severe consequences, including pulp necrosis, inflammatory root resorption, replacement resorption and ankylosis, and loss of marginal bone support.¹³ Treatment options

Table 3 - Treatment guidelines for lateral luxation injuries

	Immature (open apex)	Mature (closed apex)
Repositioning	<ol style="list-style-type: none"> 1. With minimal displacement, spontaneous repositioning may occur, usually within 6 months. 2. With severe displacement, extraction may be recommended. Gentle repositioning can be done, and if the tooth is unstable, a flexible splint can be placed for 4 weeks. 	Reposition the tooth digitally into its original position under local anesthesia. A flexible splint should be applied for 4 weeks, or if marginal periodontal breakdown is present, additional splinting may be indicated.
Endodontic Considerations	A 2-week follow-up should be scheduled for endodontic evaluation. Teeth with incomplete root formation may revascularize. If pulp necrosis or external inflammatory root resorption is present, non-surgical root canal treatment is indicated.	A 2-week follow-up should be scheduled for an endodontic evaluation. Pulp necrosis is likely to result in teeth with complete root formation; endodontic treatment is indicated with intracanal Ca(OH) ₂ to prevent external inflammatory root resorption.

Figure 2

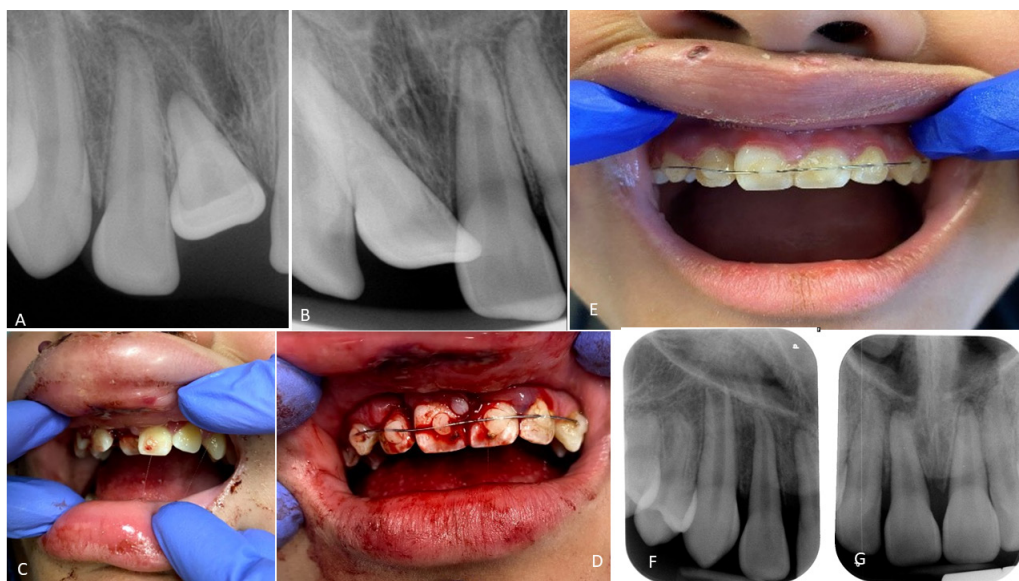

Figure 2. Diagnosis and management of lateral luxation in an 11-year-old male patient resulting from facial trauma due to a car accident.
 A - Intraoral examination revealed tooth #6 partially erupted, teeth #7, #9, and #10 showed class II mobility, and tooth #8 showed class III mobility and was palatally luxated with an alveolar fracture. B, C - Radiographic examination revealed teeth #7, #9 and #10 with subluxation and tooth #8 with lateral luxation (palatally ~8mm). Treatment was completed under IV sedation. D - Tooth #8 was repositioned and aligned with the maxillary arch dentition. An anterior flexible splint (0.16 ortho wire) was placed from tooth #4-#11, along with interproximal sutures. E-G - After 4-weeks teeth #7, #8, #9 and #10 showed healing of soft tissues, positive response to cold, and absence of radiographic signs of disease.

include observation for spontaneous re-eruption, surgical and/or orthodontic repositioning.¹³

a) Clinical Examination: The tooth may be partially or entirely intruded into the alveolar bone and is almost always immobile. In severe cases, when the tooth is entirely intruded into the socket, careful radiographic examination is required to avoid misdiagnosing an intrusive luxation as avulsion. A complete clinical and radiographic assessment must be performed to assure proper clinical management. Percussion on the affected tooth may yield a high-pitched metallic sound.⁶ Depending on the stage of tooth development and the extent of the intrusion, the tooth is likely to show a negative response to pulp sensibility testing. Clinical photographs are strongly recommended for adequate documentation of the injury.

b) Radiographic Examination: At a minimum, one parallel periapical radiograph, two periapical radiographs taken at different angulations and one occlusal radiograph are recommended.⁶ These radiographs may reveal that the cemento-enamel junction is located more apically than adjacent teeth. Dentists should also pay close attention to any radiographic signs of marginal bone breakdown or alveolar fracture. CBCT is also strongly recommended to provide tridimensional information about the degree of intrusion, the condition of the surrounding bone structure and the presence of tooth and/or bone fracture(s).

Figure 3

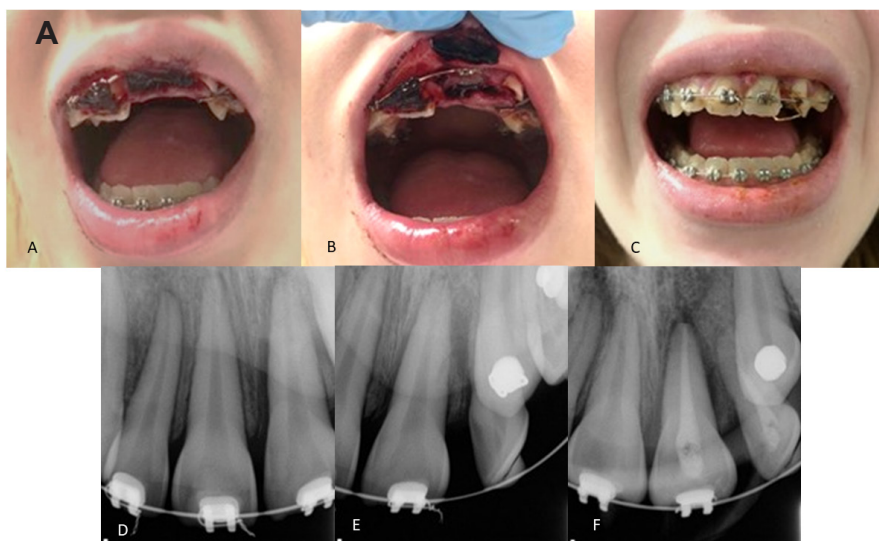


Figure 3. Diagnosis and management of intrusive luxation. A 15-year-old female presented to the emergency room due to traumatic dental injuries affecting teeth #7 through #10. A & B - Clinical and radiographic examination showed concussion of teeth #7 and #8, and an 8-mm intrusive luxation of teeth #9 and #10. Teeth #9 and #10 were surgically repositioned and a physiologic splint was bonded from teeth #5 through #13. C – F - Clinical and radiographic observations after 1 week. Teeth #9 and #10 (intrusive luxation) did not respond to a cold test, while teeth #7 and #8 (concussion) responded normally. Endodontic therapy was initiated on teeth #9 and #10; Ca(OH)₂ paste was used as an intracanal medicament for a month.

c) Treatment: Current guidelines are primarily based on the stage of the root formation (immature vs. mature permanent teeth). (Table 4)

d) Follow-up Examination: The injured tooth should be monitored clinically and radiographically

at two weeks, four weeks, eight weeks, twelve weeks, six months, twelve months, and yearly after that for a minimum of five years. The splint may be removed after four weeks.⁶ Dentists must emphasize the importance of regular follow-up

Table 4 - Treatment guidelines for intrusive luxation injuries⁴

	Immature (open apex)	Mature (closed apex)
Repositioning	<ol style="list-style-type: none"> 1. Allow re-eruption without intervention as the initial step for all intruded teeth independent of the degree of intrusion 2. If no re-eruption occurs within 4 weeks, initiate orthodontic repositioning 	<ol style="list-style-type: none"> 1. If intrusion is <3mm: allow re-eruption without intervention. If no re-eruption occurs within 8 weeks, reposition surgically and splint for 4 weeks with a passive and flexible splint. Alternatively, reposition orthodontically to prevent ankylosis 2. If intrusion is 3-7mm: reposition surgically or orthodontically 3. If intrusion is >7mm: reposition surgically
Endodontic Considerations	<ol style="list-style-type: none"> 1. Monitor the pulp status as spontaneous revascularization may occur 2. If the pulp becomes necrotic, or signs are indicating inflammatory resorption, appropriate endodontic therapy for immature teeth should be initiated as soon as the condition of the tooth permits. 	<ol style="list-style-type: none"> 1. Pulp necrosis is a common consequence 2. Endodontic therapy should be initiated at 2 weeks or as soon as the condition of the tooth permits; placement of an intracanal medicament (corticosteroid-antibiotic or Ca(OH)₂) is recommended

examinations to the patient and parents/ guardians at the initial appointment. Dentists should also discuss possible favorable/unfavorable outcomes and alternative treatment options.

Avulsion

Avulsion is a severe dental injury where a tooth has been completely displaced from the socket. With this type of trauma, interventions at the time of injury and shortly after can dramatically affect the ultimate prognosis. In most cases, immediate replantation of the avulsed tooth is the treatment of choice.^{8,14} Since avulsion commonly occurs in children, it is essential to determine whether the avulsed tooth is primary or permanent. Primary teeth should not be replanted.⁸ If a permanent tooth cannot be replanted at the accident site, the

tooth should be immediately placed in a storage medium such as Hank's Balanced Salt Solution, milk, saliva or saline to avoid dehydration of cells on the root surface.⁸ The patient should then seek treatment from a dentist immediately.

An extraoral dry time of greater than 60 minutes is considered a delayed replantation. There is a critical link between periodontal cells viability and extra alveolar dry time.⁴ Even though these cases have a poor long-term prognosis due to necrosis of the periodontal ligament with subsequent ankylosis and replacement resorption, replanting will temporarily maintain esthetics for the patient and help to preserve the alveolar bone for future treatment options.⁸ No treatment to the root surface is indicated prior to the re-implantation, other than

gross removal of obviously damaged PDL tissue.⁴ Thus, the decision to replant permanent teeth is warranted, even with prolonged extraoral dry times.

a) Clinical and Radiographic Examination:

After a rapid neurologic assessment, if the tooth has been replanted before arrival at the dental office, the correct position of the tooth should be verified clinically and radiographically. If the tooth has not been replanted, place the tooth in a storage medium while completing the history, clinical and radiographic exam. After administering local anesthesia, gently rinse any visible debris from the root surface, being careful not to aggressively clean the root surface to ensure maintenance of soft tissue, and then replant the

Table 5 - Treatment guidelines for avulsed permanent teeth with an open apex⁸

Tooth was replanted at the site of injury (open apex)	Tooth has not been replanted, regardless of time (open apex)
1. Gently clean the affected area with water, saline, or chlorhexidine.	1. Gently rinse the root with sterile saline, milk, or Hanks' Balanced Salt Solution (HBSS) if contamination of root surface is visible.
2. Clinically and radiographically verify that the tooth has been replanted correctly.	2. Place the tooth in storage medium while taking history, performing a clinical and radiographic exam.
3. If incorrect positioning is noted (the tooth is rotated or replanted in the wrong socket), repositioning within 48 hours of the injury is recommended.	3. Administer local anesthesia, preferably without a vasoconstrictor.
4. Place a flexible splint for 2 weeks.	4. Irrigate the socket using sterile saline.
5. Suture any gingival lacerations.	5. Examine for fracture of the alveolar socket wall - if present, reposition the fractured fragment.
6. Pulp revascularization is the ideal outcome; however, endodontic therapy should be initiated immediately if inflammatory resorption or pulp necrosis is identified.	6. Using slight digital pressure, slowly replant the tooth.
7. Administer systemic antibiotics based on patient's age and weight.	7. Verify the correct position of the replanted tooth clinically and radiographically.
8. Check tetanus status.	8. Stabilize the tooth for 2 weeks using a passive flexible splint.
9. Provide post-operative instructions.	9. Suture gingival lacerations, if present.
10. Follow-up.	10. Pulp revascularization is the ideal outcome; however, endodontic therapy should be initiated immediately if inflammatory resorption or pulp necrosis is identified.
	11. Administer systemic antibiotics based on the patient's age and weight.
	12. Check tetanus status.
	13. Provide post-operative instructions.
	14. Follow-up.

tooth with light pressure. The correct position of the tooth should be verified clinically and radiographically. The tooth should be stabilized with a flexible splint for two weeks. Systemic antibiotics are recommended after replanting an avulsed tooth. They may help prevent infection and decrease the incidence of inflammatory root resorption. The first choice should be amoxicillin or penicillin at the appropriate dosage for the patient's age and weight.⁸ For penicillin-allergic patients, doxycycline can be given to patients over the age of twelve. Azithromycin should be prescribed for patients under twelve years old due to the risk of tooth discoloration in young patients administered doxycycline. The patient should be referred to a physician to evaluate the need for a tetanus booster.⁸

b) Treatment: At the two-week follow-up appointment, endodontic treatment should be initiated in teeth with a closed apex. Calcium hydroxide should be placed as an intracanal medicament for approximately four weeks, after which the tooth can be obturated. The splint should be removed following the initiation of endodontic treatment at this two-week follow-up appointment. Pulp revascularization is possible in teeth with an open apex; endodontic treatment should be initiated for open apex teeth only when there are signs and symptoms of pulp necrosis and infection. Inflammatory root resorption can progress rapidly in children, so frequent follow-up examinations are necessary when pulp revascularization is anticipated. It is essential to emphasize the necessity of these regular follow-up examinations to the patient or guardian at the initial appointment.

c) Follow-up Examinations: Clinical and radiographic monitoring is recommended at a minimum of two weeks (when the splint is removed), four weeks, three months, six months, twelve months, and yearly for at least five years.⁸

Prognosis/Complications

The incidence of dental pulp necrosis, dental pulp survival and pulp canal space obliteration following each type of luxation injury^{9,10} are summarized below (**Figures 5 and 6**). Please note that avulsion is not included in the figures due to the variable nature of outcome dependent on many factors such as extraoral dry time, type of storage medium, and stage of root development. However, as a general guideline, the survival rate following avulsion is higher in teeth with open vs closed apex.

Table 6 - Treatment guidelines for avulsed permanent teeth with a closed apex⁸

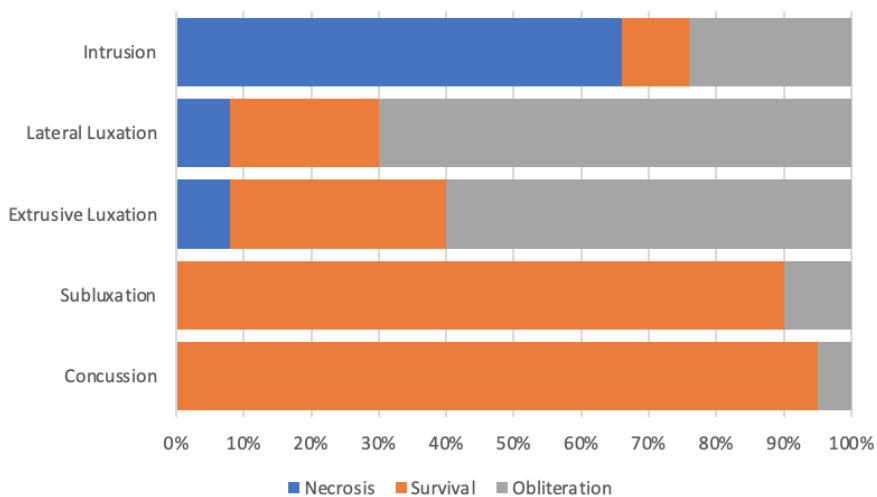
Tooth was replanted at the site of injury (closed apex)	Tooth has not been replanted, regardless of time (closed apex)
1. Gently clean the affected area with water, saline, or chlorhexidine	1. If there is visible contamination of root surface, gently rinse the root with sterile saline, milk, or HBSS.
2. Verify the correct position of the replanted tooth both clinically and radiographically	2. Place the tooth in storage medium while taking history, performing a clinical exam, and preparing the patient for replantation.
3. If incorrect positioning is noted (the tooth is rotated or replanted in the wrong socket), repositioning within 48 hours of the injury is recommended	3. Administer local anesthesia, preferably without a vasoconstrictor.
4. Stabilize the tooth for 2 weeks using a passive flexible splint	4. Irrigate the socket with sterile saline.
5. Suture gingival lacerations if present	5. Examine for fracture of the alveolar socket wall - if present, reposition the fractured fragment.
6. Initiate root canal treatment within 2 weeks after replantation	6. Using slight digital pressure, slowly replant the tooth.
7. Administer systemic antibiotics	7. Verify the correct position of the replanted tooth clinically and radiographically.
8. Check tetanus status	8. Stabilize the tooth for 2 weeks using a passive flexible splint.
9. Provide post-operative instructions	9. Suture gingival lacerations, if present.
10. Follow-up	10. Initiate root canal treatment within 2 weeks after replantation.
	11. Administer systemic antibiotics.
	12. Check tetanus status.
	13. Provide post-operative instructions.
	14. Follow-up.

Figure 4

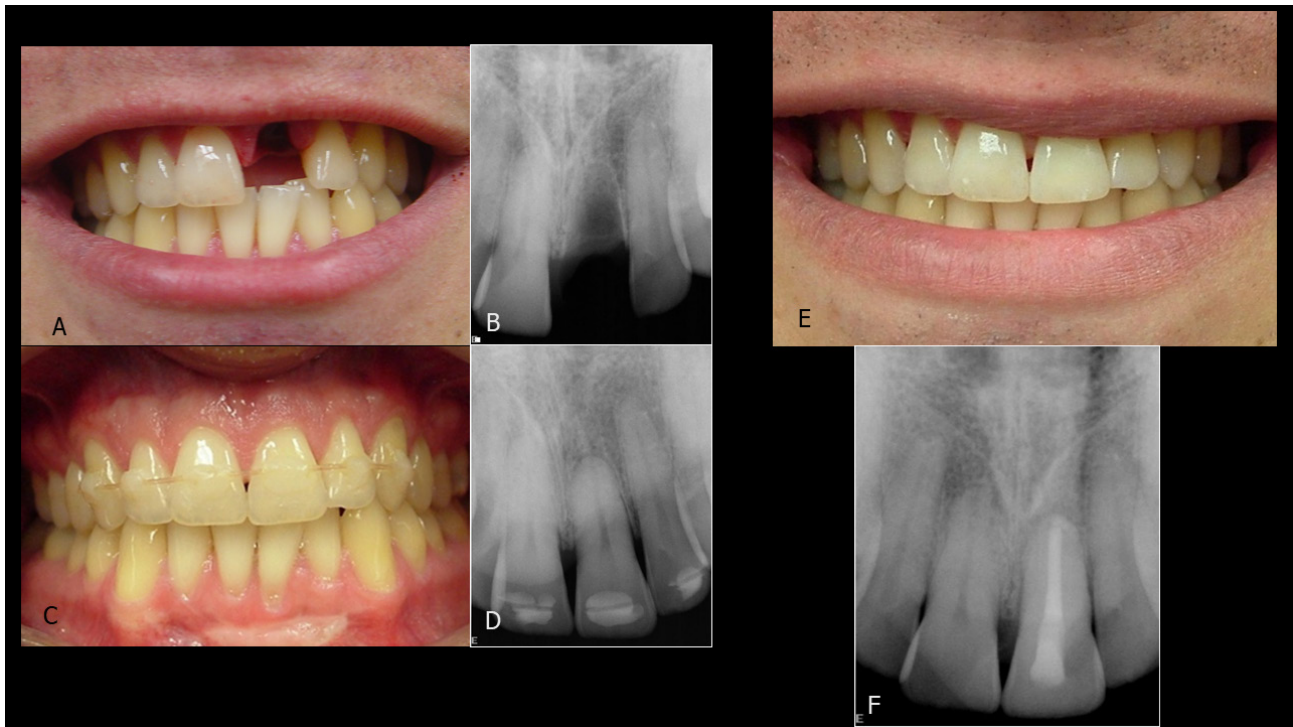

Figure 4. Diagnosis and management of permanent tooth avulsion. A, B - Clinical and radiographic presentation of avulsed tooth #9. Note that the tooth is entirely out of its socket. C, D, Tooth #9 was replanted in its original position followed by placement of a physiologic splint (monofilament fishing line with composite resin). E - F, Patient at two weeks post-replantation, nonsurgical root canal treatment was performed, and the splint was removed. (Courtesy of Dr. Michael Suhler)

Figure 5 - Complications/Survival prognosis following luxation injury for teeth with open apex.^{9,10}



Summary

Since traumatic dental injuries are common, it is important for dentists to be able to diagnose, treat and manage appropriately to improve the prognosis and provide the best care possible for the patient promptly and accurately. The initial examination of a traumatic situation should not only focus on the intraoral soft and hard tissue structures, but also include a rapid neurological assessment and evaluation for any signs of brain concussion or other head and neck injuries. Appropriate referrals should be made to physicians and/or other dental specialists as needed. It is essential for dentists to have an informed discussion with parents and patients regarding the possible outcomes and prognosis for each type of dental injury as well as the need to adhere to the recommended recall intervals to monitor pulpal status, as some cases may not require endodontic intervention depending on the stage of root development and type of dental injury.

This Quality Resource Guide aims to provide dentists with a step-by-step guidance on how to recognize, diagnose (through appropriate clinical and radiographic examination), treat and manage various traumatic dental injuries, with emphasis on the endodontic considerations following each type of injury. A decision-making flowchart in the figure below may be used during initial evaluation in conjunction with the information outlined in this guideline. It is important to note that this guidance is limited to luxation injuries and does not provide information regarding fracture injuries such as root fracture and/or alveolar fracture that may occur following trauma. For information pertaining to those types of traumatic dental injury, we strongly recommend the free *ToothSOS* app.

Figure 6 - Complications/Survival prognosis following luxation injury for teeth with closed apex.^{9,10}

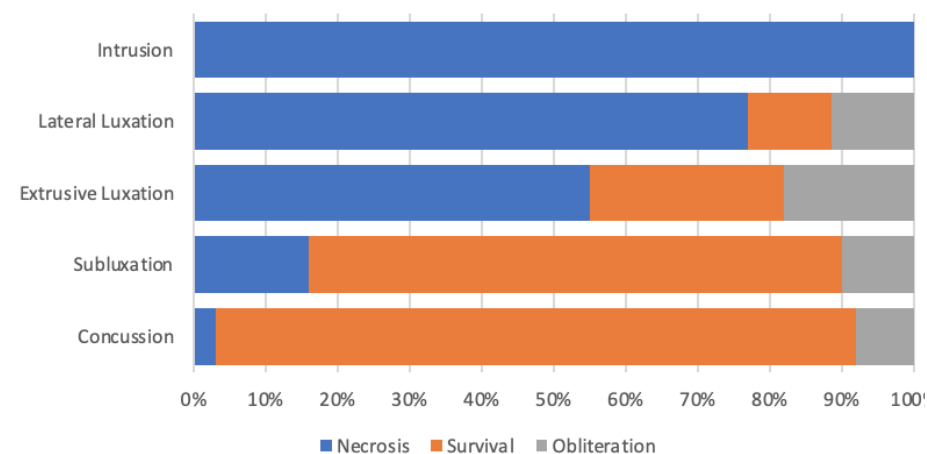
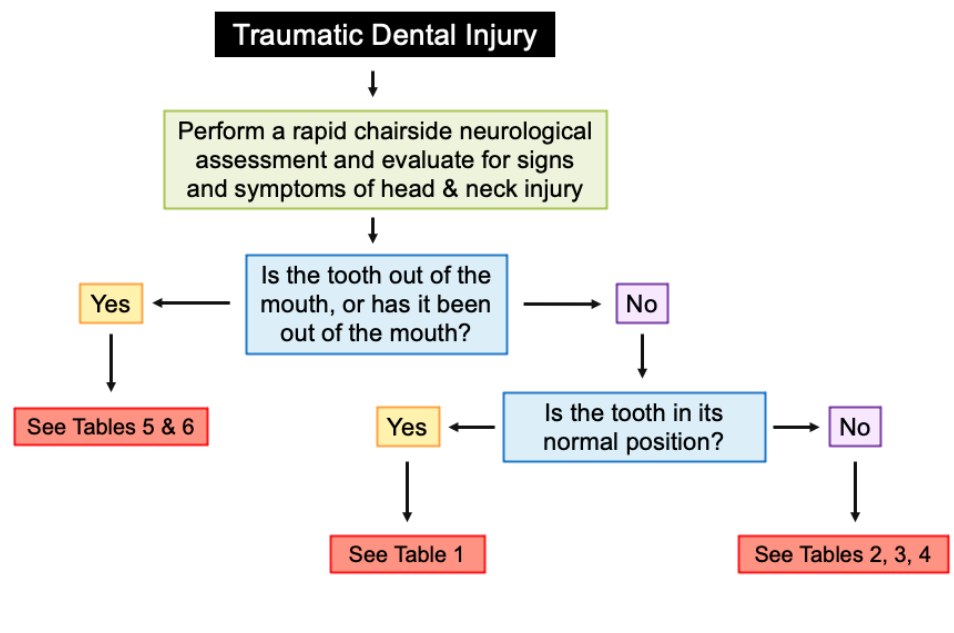


Figure 7 - Traumatic dental injury decision making flowchart



References

1. Petti S, Glendor U, Andersson L. World traumatic dental injury prevalence and incidence, a meta-analysis-One billion living people have had traumatic dental injuries. *Dent Traumatol.* 2018;34(2):71-86.
2. Kaste LM, Gift HC, Bhat M, Swango PA. Prevalence of incisor trauma in persons 6-50 years of age: United States, 1988-1991. *J Dent Res.* 1996;75 Spec No:696-705.
3. Levin L, O'Connell AC, Tewari N, Mills SC, Stasiuk H, Roettger M, et al. The International Association of Dental Traumatology (IADT) and the Academy for Sports Dentistry (ASD) guidelines for prevention of traumatic dental injuries: Part 1: General introduction. *Dent Traumatol.* 2024;40 Suppl 1:1-3.
4. Burns B, Malcolm L. A review of the iadt 2020 guidelines. *Prim Dent J.* 2023;12(4):22-7.
5. Levin L, Day PF, Hicks L, O'Connell A, Fouad AF, Bourguignon C, et al. International Association of Dental Traumatology guidelines for the management of traumatic dental injuries: General introduction. *Dent Traumatol.* 2020;36(4):309-13.
6. Bourguignon C, Cohenca N, Lauridsen E, Flores MT, O'Connell AC, Day PF, et al. International Association of Dental Traumatology guidelines for the management of traumatic dental injuries: 1. Fractures and luxations. *Dent Traumatol.* 2020;36(4):314-30.
7. Kahler B, Hu JY, Marriot-Smith CS, Heithersay GS. Splinting of teeth following trauma: a review and a new splinting recommendation. *Aust Dent J.* 2016;61 Suppl 1:59-73.
8. Fouad AF, Abbott PV, Tsilingaridis G, Cohenca N, Lauridsen E, Bourguignon C, et al. International Association of Dental Traumatology guidelines for the management of traumatic dental injuries: 2. Avulsion of permanent teeth. *Dent Traumatol.* 2020;36(4):331-42.
9. Tewari N, Abbott PV, O'Connell AC, Mills SC, Stasiuk H, Roettger M, et al. The International Association of Dental Traumatology (IADT) and the Academy for Sports Dentistry (ASD) guidelines for prevention of traumatic dental injuries: Part 8: ToothSOS app. *Dent Traumatol.* 2024;40 Suppl 1:18-9.
10. Andreasen FM, Pedersen BV. Prognosis of luxated permanent teeth--the development of pulp necrosis. *Endod Dent Traumatol.* 1985;1(6):207-20.
11. Dumsha TC. Luxation injuries. *Dent Clin North Am.* 1995;39(1):79-91.
12. Day PF, Flores MT, O'Connell AC, Abbott PV, Tsilingaridis G, Fouad AF, et al. International Association of Dental Traumatology guidelines for the management of traumatic dental injuries: 3. Injuries in the primary dentition. *Dent Traumatol.* 2020;36(4):343-59.
13. Oulis C, Vadiakas G, Siskos G. Management of intrusive luxation injuries. *Endod Dent Traumatol.* 1996;12(3):113-9.
14. Tewari N, Abbott PV, O'Connell AC, Mills SC, Stasiuk H, Roettger M, et al. The International Association of Dental Traumatology (IADT) and the Academy for Sports Dentistry (ASD) guidelines for prevention of traumatic dental injuries: Part 10: First aid education. *Dent Traumatol.* 2024;40 Suppl 1:22-4.

POST-TEST

Internet Users: This page is intended to assist you in fast and accurate testing when completing the “Online Exam.” We suggest reviewing the questions and then circling your answers on this page prior to completing the online exam.

(1.0 CE Credit Contact Hour) Please circle the correct answer. 70% equals passing grade.

1. Patient presents to the clinic after traumatic dental injury, and you noticed a luxated tooth that appears elongated in an incisal/axial direction with bleeding around the gingival sulcus. This is a clinical presentation of _____.
 - a. Intrusive luxation
 - b. Lateral luxation
 - c. Extrusive luxation
 - d. Concussion
2. A patient presents with a subluxation injury to tooth #8. There are no notable radiographic findings. The tooth is class II mobile with tenderness to percussion but no tenderness or fremitus upon biting. Electric pulp testing and cold testing do not elicit a pulpal response and the surrounding teeth test within normal limits. Which treatment is indicated at this appointment?
 - a. Endodontic treatment should be initiated immediately due to the negative response to sensibility testing
 - b. A rigid splint should be placed for one month to eliminate any mobility
 - c. The tooth should be extracted due to poor long-term prognosis of traumatized teeth
 - d. No treatment is indicated; however, the patient should be followed-up to monitor for pulp necrosis
3. A patient presents for treatment after being hit in the face with a softball. There are no notable radiographic findings and all teeth test within normal limits to sensibility testing. All teeth appear in their normal position and the patient has no pain when occluding. Tooth #8 is non-mobile but very sensitive to percussion. Tooth #9 is sensitive to percussion and presents with class II mobility. The diagnoses for teeth #8 and #9 are:
 - a. Tooth #8 concussion; Tooth #9 subluxation
 - b. Tooth #8 normal apical tissues; Tooth #9 extrusive luxation
 - c. Tooth #8 subluxation; Tooth #9 lateral luxation
 - d. Tooth #8 subluxation; Tooth #9 concussion
4. For an immature tooth (open apex) with an intrusive luxation injury, allowing re-eruption without intervention is the first step. If no re-eruption occurs within _____ weeks, one should initiate orthodontic repositioning.
 - a. two
 - b. four
 - c. six
 - d. eight
5. If the intrusion is more than _____ millimeters (mm) for a mature tooth (closed apex) with an intrusive luxation injury, surgical repositioning is the preferred choice of treatment.
 - a. 1
 - b. 3
 - c. 5
 - d. 7
6. The best place to store an avulsed tooth is in:
 - a. a glass of milk.
 - b. its own socket.
 - c. a bottle of water.
 - d. a dry napkin.
7. What is the incidence of pulp necrosis following intrusion injury for teeth with closed apex?
 - a. 40%
 - b. 60%
 - c. 80%
 - d. 100%
8. Favorable outcome(s) following extrusive luxation injury include(s)?
 - a. Positive response to pulp testing
 - b. Continuing root development
 - c. Absence of marginal bone loss
 - d. All of the above
9. An ideal splint should not:
 - a. Induce replacement resorption to promote periodontal ligament reattachment.
 - b. Stabilize the injured tooth/teeth in its correct position.
 - c. Be easily applied and removed without additional trauma.
 - d. Allow functional movement of the affected tooth.
10. After repositioning a tooth that has incurred a lateral luxation injury, a flexible splint should be placed for:
 - a. one week.
 - b. two weeks.
 - c. four weeks.
 - d. twelve weeks.

